

## ORIGINAL ARTICLE

## BASAL CELL CARCINOMA EXCISION INTRAOPERATIVE FROZEN SECTION FOR TUMOUR CLEARANCE RATE AND RECONSTRUCTIVE SURGERY

Moizza Tahir<sup>1✉</sup>, Uzma Bashir<sup>1</sup>, Aisha Akhtar<sup>1</sup>, Sidiqua Javaid<sup>1</sup>, Zainab Ansari<sup>2</sup>, Sameen Ansari<sup>2</sup>

<sup>1</sup>Department of Dermatology, Pak Emirates Military Hospital Rawalpindi-Pakistan

<sup>2</sup>Army Medical College, Rawalpindi-Pakistan

**Background:** Basal cell carcinoma (BCC) is the most common skin cancer. Its annual incidence in US is 2 million per year with an increase of 0.87%. The objective was to report intraoperative frozen section clearance rate of tumour margins and depth for excised basal cell carcinoma in a tertiary care centre and find the frequency of tumour in surgical margins with respect to location, size, and surgical reconstruction technique. **Method:** It was a prospective open-label interventional study conducted at the Dermatology department of tertiary care hospital Rawalpindi (Pakistan) in liaison with the histopathology department from January 2023 to April 2024. The patients with clinical diagnosis of basal cell carcinoma, of 10–35 mm located on the face were included as per inclusion/exclusion criteria. An intraoperative frozen section for tumour margins and depth was taken from a histopathologist. The surgical defect was reconstructed after the negative report. *p*-value of <0.05 was considered significant for margin involvement, surgical technique, and location. **Results:** A total of 36 patients of BCC were enrolled. Tumour-free margins and depth were attained in 77.77% of cases. Tumour excision with a frozen section concerning surgical technique had a chi-square *p*-value ≤0.51, location ≤0.24, and size ≤0.84. **Conclusion:** Intraoperative frozen section for basal cell carcinoma is a reliable technique for complete tumour excision. This technique is resource-intensive and time-consuming. It should be reserved for tumours at high-risk sites, and require complex reconstruction. Patients should be educated for follow up in case of induration, morphological changes, or new developments in surgical scar.

**Keywords:** BCC frozen section; BCC face reconstruction technique and tumour free margin; Tumour free margin, BCC excision

**Citation:** Tahir M, Bashir U, Akhtar A, Javaid S, Ansari Z, Ansari S. Basal cell carcinoma excision intraoperative frozen section for tumour clearance rate and reconstructive surgery. J Ayub Med Coll Abbottabad 2024;36(4):692–7.

DOI: 10.55519/JAMC-04-13800

### INTRODUCTION

Basal cell carcinoma (BCC) is the most common skin cancer. The majority of BCC are in Europe, US and Australia. Annual incidence in US is 2 million per year with an increase of 0.87%.<sup>1</sup> In skin of color (SOC) sun exposure causes photodamage, dyschromia and BCC. Photoprotection in SOC is primarily focused on dyschromias and photoaging, with comparatively less emphasis on the prevention of BCC.<sup>2</sup> Women are now affected more than man. The nodular BCC is more common on the head and neck while superficial spreading BCC is on the torso.<sup>3</sup> BCC is the most common skin cancer in Pakistan.<sup>4,5</sup>

National Comprehensive Cancer Network (NCCN) guidelines state low-risk BCC, as nodular, superficial spreading, and primarily located on sites L (trunk and extremities), <20 mm in size, or on sites M (cheeks, forehead, scalp, neck, and pretibial) and <10 mm in size. BCC located on sites L (trunk and extremities) >20 mm or/ and M (cheeks, forehead,

scalp, neck, and pretibial) >10 mm in size, H (central face, eyelids, eyebrows, periorbital skin, nose, lips, chin, mandible, preauricular and postauricular skin/sulci, temple, ear, genitalia, hands and feet), at radiation site, in patients on immunosuppression and with pathologic pattern of morpheaform or basisquamous are as high risk.<sup>6</sup> Mohs micrographic surgery (MMS) or margin control techniques are the gold standard, especially in high-risk BCCs offering maximum cure.<sup>7</sup> The European Dermatology Forum (EDF) guidelines recommend a safety margin of 3mm for an 85% cure rate, whereas NCCN recommends 4 mm for low-risk and 6 mm for high-risk BCC. An elliptical excision with a safety margin of 4 mm of normal skin is often not possible because of cosmetic and functional limitations of the face. A narrow safety margin can be kept for small, well-demarcated pigmented BCC located in more cosmetic and sensitive anatomical sites.<sup>8</sup> However, margin involvement after BCC excision results in recurrence only in a proportion of patients.<sup>9</sup> The excision margin

of 1–5 mm has been described as safe with no statistically significant recurrence.<sup>8</sup> Mohs micrographic surgery (MMS) and tissue processing techniques has subjective variations in approach with the highest cure rates.<sup>10,11</sup> Rehman SH et al in quantitative analyses of skin cancer research in Pakistan reported cancer publications as 2.7 per year. Punjab Cancer Registry (PCR) has reported skin cancer as the 9th, and the Karachi Cancer Registry (KCR) reported it as the 8th common cancer. There is a need for appropriate diagnostic, therapeutic, and prognostic evaluation for skin cancers.<sup>12</sup> The present study aims to report the utility of intraoperative frozen section (FS) histopathological clearance rate for excision of BCC in a tertiary care center and find the frequency of tumours in surgical margin with reference to location, size and reconstruction technique.

**MATERIAL AND METHODS**

This Prospective study was conducted at a tertiary care hospital of Rawalpindi Pakistan from 1st Jan 2023 till 16th May 2024. The institutional ethical review board approved the study. A sample size of 36 was calculated with a 95% confidence interval, the margin of error 5%, population proportion of 2% with Epi Info sample size calculator.<sup>13,14</sup> Patients with a clinical diagnosis of primary BCC on the head and neck were enrolled in the study by purposive sampling technique after informed consent. Patients with BCC size greater than 35 mm, recurrent lesions, past history of treatment such as cryotherapy, electrocautery, topical 5FU, Imiquimod cream, non-melanoma skin cancer (NMSC) surgery, patients on anticoagulants, and BCC involving eyelids and ears were excluded. All patients underwent SE of BCC with a margin of 2–3 mm under infiltrative local anaesthesia (lignocaine hydrochloride 2% with adrenaline 1 in 80 000) at the Dermatology Department by a consultant Dermatologist. A prior appointment with a histopathologist was made for frozen section (FS) analysis on the telephone. Intraoperative FS consultation for margin and depth clearance by liaison with a histopathologist was again done on the telephone. Margins of the resected lesion were tagged as 6, 9, 12 & 3 ‘o’clock and sent in normal saline, with documentation of the patient’s particulars, site, and morphology of BCC. After the clearance report from the histopathologist surgical defect was reconstructed by primary closure, rotation, or advancement flaps and sec intention under aseptic measures with proline 4/0. Haemostasis was secured. Anti-septic dressing was employed and patients were reviewed on 2nd post-op day. Stitches were removed on the 7th post-operative day. The final histopathology report was re-examined on the 10th day for margin and depth clearance.

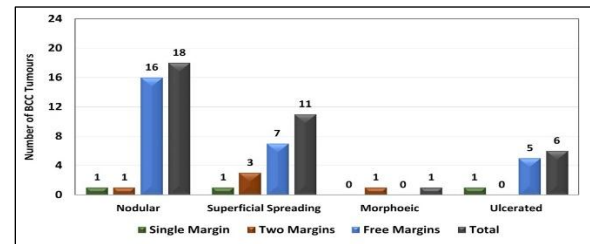
Data was analyzed by SPSS 27. Descriptive statistics were calculated for age, gender, reconstructive technique, location, tumour-free margin rate, involved margins, and depth involvement report on frozen section analysis. The chi-square test was employed for statistical significance of the involvement of surgical margin rate concerning location, size, and reconstructive surgical technique, *p* value of <0.05 was considered significant.

**RESULTS**

A total of 36 patients of BCC were enrolled, males 12 (33.3%) and females 24 (66.6%). Age ranged from 45 years to 80 years mean of 58.36±SD 7.8. The size of BCC ranged from 5 mm to 35 mm mean of 25 mm ±SD 0.63. The anatomical location of BCC is shown in table 1. Morphology was as nodular in 18 (50%), superficial spreading in 11 (30.6%), morphoeic in 1 (2.8%), and ulcerative in 6 (16.7%) cases. Six patients (16.7%) had hypertension, and 29 (80.6%) had no comorbid. Nine (25%) were graduates, 9 (25%) completed primary school and 18 (50%) secondary school. Fourteen (38.9%) had office jobs, and 22 (61.1%) had fieldwork. Two (5.6%) were residents of Gujranwala, 9 (25%) were from Kashmir, 20 (55.6%) Rawalpindi, and 5 (13.9%) were from Muzaffarabad.

Primary closure was performed in 15 (41.7%), advancement flap was performed in 10 (27.8%), rotation flap in 9 (25%), and the surgical defect was left open to heal by secondary intention in 2 (5.6%) cases. The morphology of BCC and tumour-free margin is shown in Figure-1

Excised tumour depth was uninvolved in all cases. There was no statistically significant relationship of tumor margin involvement with its size chi-square *p*-value of 0.84, location chi -square *p*-value of 0.24, and reconstruction technique *p*-value of 0.515.



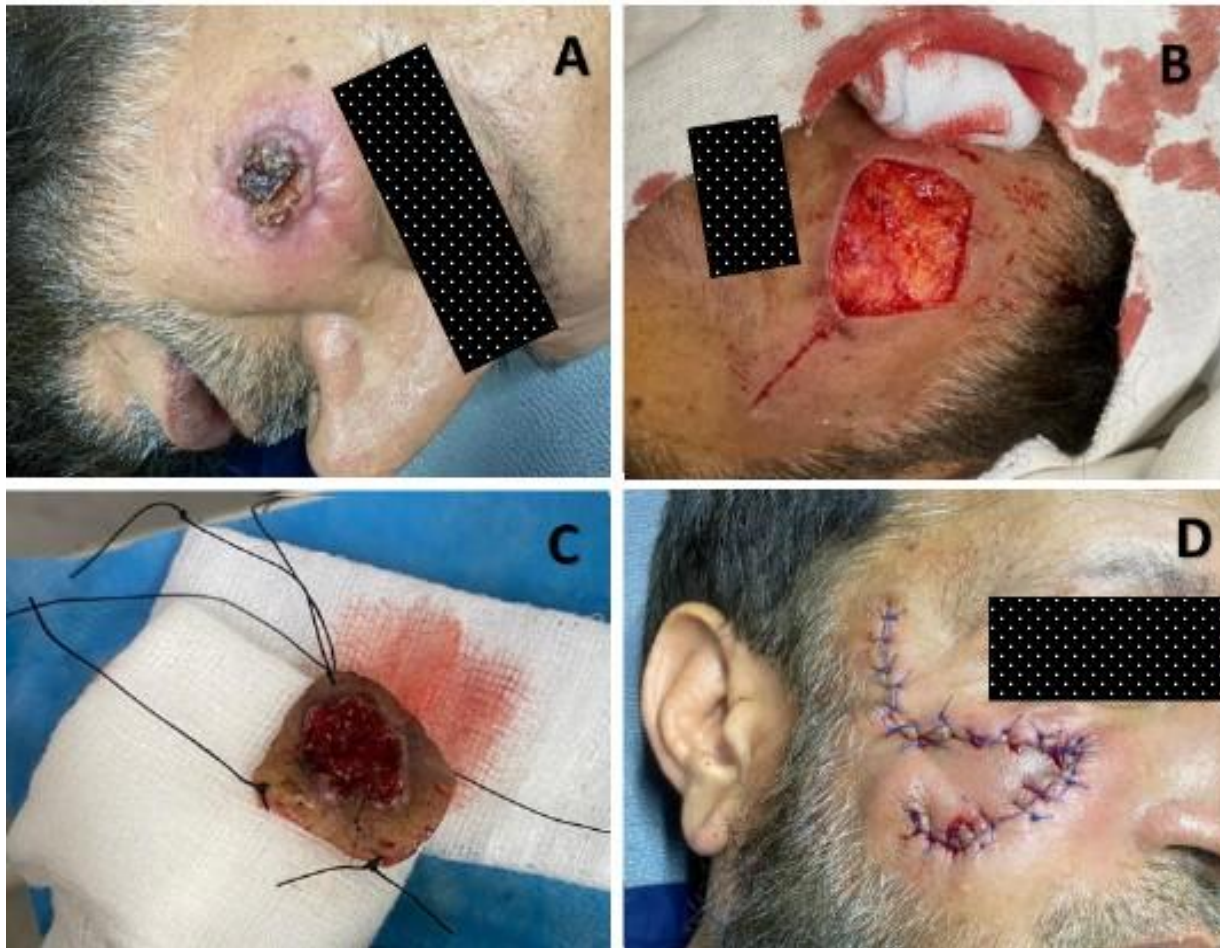**Figure-1: Tumour-free margins rate in various types of BCC**

**Table 1: Frequency of BCC Locations of Face**

Anatomical Location	No (Total: 36)
Forehead	6 (16.7%)
Temple	3 (8.3%)
Nose	9 (25%)
Cheek	14 (38.8%)
Lip	1 (2.7%)
Infraorbital	4 (11.11%)

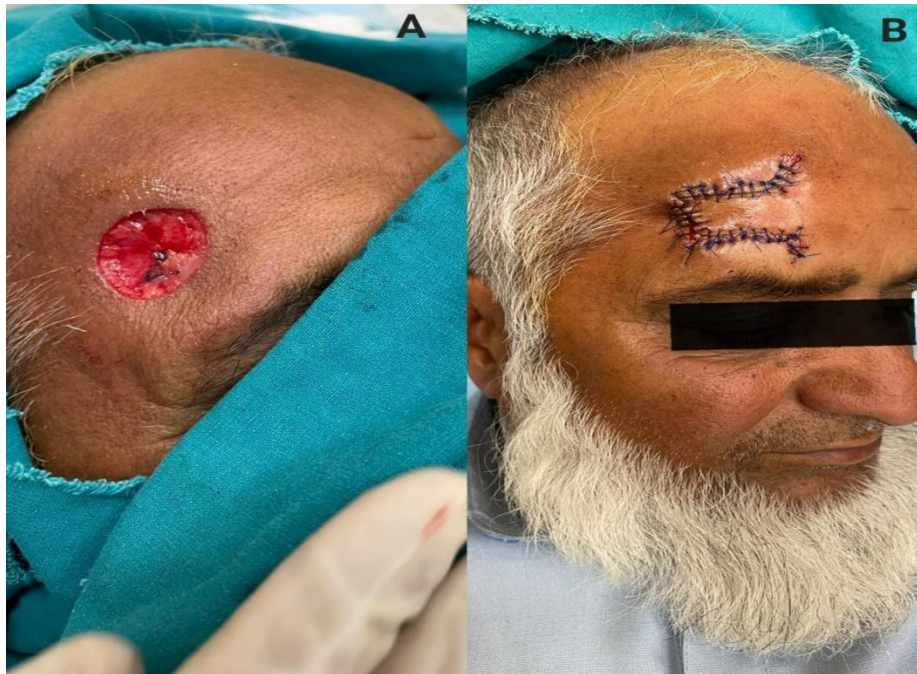**Table-2: Chi-square *p*-value for intraoperative Frozen section marginal clearance rate and its correlation with location, size, and reconstruction technique.**

Parameter	Tumour involvement of margin				Chi-square <i>p</i> -value
	All Tumour Margins (n)	Single Margin (n)	Two Margins (n)	Total (n)	
Size (mm)					0.84
10	1	0	0	1	
15	3	0	0	3	
20	9	0	1	10	
25	4	1	0	5	
28	1	0	0	1	
30	8	2	3	13	
35	2	0	1	3	
	28	3	5	36	
Location					0.24
Forehead	5	0	1	6	
Temple	1	1	0	2	
Nose	4	1	1	6	
Cheek	14	1	3	18	
Lip	0	0	0	0	
Infraorbital	4	0	0	4	
<b>Reconstruction Technique after the Intraoperative Frozen section for tumour margin clearance rate</b>					
Prim closure	13	0	2	15	0.515
Rotation Flap	5	2	2	9	
Advancement Flap	8	1	1	10	
Healing by secondary intention	2	0	0	2	



**Figure-2: A. Nodulo-ulcerative BCC B. Excised under local anaesthesia C. BCC margins are tagged with threads at 12, 3, 6 and 9 'o' clock position for frozen section clearance D. Surgical defect is reconstructed after FS Histopathology report**





**Figure-3: (A) BCC surgical defect (B) Single advancement flap**

## DISCUSSION

Basal cell carcinoma subclinical extension is observed in high-risk sites, tumour recurrence, size >10 mm, and aggressive subtype. Well-defined BCC may need excision of small margins for clearance but relatively larger margins are required for superficial, micronodular, infiltrative, and morphea form BCC. It is important to classify BCC as low and high risk for management plan.<sup>15</sup> Training in Mohs Micrographic Surgery (MMS) is in demand in Pakistan.<sup>16</sup> Recommended follow-up for primary BCC is 10 Years considering the probability of recurrence in 4.4% after MMS and 12.2% after surgical excision (SE). Recurrence may occur earlier than 5 years, especially for BCC at H sites of the face, positive excision margins in previous resections, or with an aggressive histological growth pattern.<sup>17</sup> SE is the gold standard treatment for BCCs, post-surgical recurrence is seen in 2–8% after 5 years. A safety margin of 2–5 mm and 5–15 mm are recommended for low- and high-risk tumours respectively.<sup>18</sup> BCC was frequent in (53.2%) of males and (46.8%) of females (1.2: 1), the excision margins were reported as clear in 82 (34.9%) cases and involved in 55 (23.4%) cases.<sup>19</sup> Hidayat Ullah *et al* in a descriptive cross-sectional study of 88 cases of low-risk BCC at Hayatabad Peshawar, found a frequency of 63.6% in males and 36.4% in females.<sup>20</sup> In a retrospective study of 382 patients of BCC in Bangladesh there was a preponderance of females (59%), as compared to males 41%.<sup>21</sup> This is in comparison to our study where BCC was frequent in

females. This difference is due to women's UV exposure in fields in rural areas of Punjab, UV triggers skin carcinogenesis, and inflammation.<sup>22</sup> Weshah *et al* in a retrospective study of 76 patients in King Hussein Medical Center (KHMC), Jordan found nodulo-ulcerative (42.1%) BCC commonest morphology and nose (46.0%) was the commonest site.<sup>23</sup> Aandani A. *et al.* in the retrospective study reported 53 BCC at the plastic surgery department of Civil Hospital Karachi; the nose (43.40%) was the commonest site and the most frequent clinical type was ulcerative (83.02%).<sup>24</sup> Jaffer N *et al* in a retrospective study of 142 NMSC, at Jinnah Post Graduate Medical Center, Karachi reported nodular variant in 56 (65.1%) cases, as the commonest.<sup>25</sup> This morphological pattern is consistent with our findings. cheek as the commonest anatomical site where as the nose was reported by Afridi RAK *et al* to be the commonest site.<sup>26</sup> Differences in sites may be due to differences in sun exposure of enrolled participants in study.

T Ito *et al.* in an observational study of excision of pigmented BCC 288 at Dermatology Department Kyushu University Japan reported 95.3% clearance with 2-mm margins and 100% with 3 mm margin.<sup>27</sup> Otsuka *et al.* in 542 skin carcinomas in intraoperative 'en face' frozen section analysis found 98% clearance of margins. We reported 77.8% clearance with 2–3 mm margin with FS followed by histopathology report.<sup>28</sup> Baber *et al* in a cross-sectional study of 51 cases found tumour-free margins in 84.3% of cases.<sup>29</sup> Intraoperative FS analysis is an acceptable

alternative to MMS as it allows a comprehensive assessment of all margins.<sup>30</sup>

The inherent limitation of our study was that follow up for tumour recurrence wasn't included in the study. The study findings of margin clearance were based on BCC lesions up to (35 mm) only. Consequently, a prospective multicenter study with a longer follow-up period is necessary to further validate and enhance our research findings. Frozen section histopathology in future may be interpreted with artificial intelligence (AI). The primary benefit of utilizing frozen sections in AI training is that it enhances the diversity of pathology-based AI training sets.

## CONCLUSION

Intraoperative frozen section for excision of basal cell carcinoma is a reliable technique as it achieved tumour-free margins in 77.7% cases, with a safety margin of 2–3 mm.

Although this technique is resource-intensive and time-consuming, patients achieve complete excision and better aesthetic outcomes. The frozen section is available in tertiary care hospitals in Pakistan. It is resource-intensive for patients living in remote areas. The frozen section for basal cell carcinoma may be reserved for patients with tumours located at high-risk sites and requiring complex reconstruction after tumour excision. Patients should be educated for follow-up visits for induration, morphological change, or new lesions or developments in previous scar.

## ACKNOWLEDGMENT

Authors acknowledge participation of patients, skin trained technicians Mohsin, Emanuel and Ahsan for their unconditional support in the study.

**Conflict of interest;** None

## AUTHORS' CONTRIBUTION

MT: Study design, Conception, Data Collection, Analysis, manuscript writing. UB: Data Collection, Analysis, manuscript editing, intellectual input. AA: Data Collection, Analysis, manuscript editing, intellectual input. SJ: Data Collection. ZA: Zainab Ansari, data collection, manuscript writing, editing, statistical analysis of data. SA: Data collection, Manuscript writing, editing, statistical analysis of data

## REFERENCES

1. Shaikh WR, Nawas ZY. Epidemiology and Risk Factors of Basal Cell Carcinoma; *Adv Treat Res* 2020;2020:1-8.
2. Tsai, J., & Chien, A. L. Photoprotection for Skin of Color. *Am J Clin. Dermatol.* 2022; 23(2);195–205. <https://doi.org/10.1007/s40257-021-00670-z>
3. Muzic JG, Schmitt AR, Wright AC, Alniemi DT, Zubair AS, Olazagasti Lourido JM, *et al.* Incidence and Trends of Basal Cell Carcinoma and Cutaneous Squamous Cell Carcinoma: A Population-Based Study in Olmsted County, Minnesota. 2000

to 2010", *Mayo Clin Proc* 2017;92(6):890–8.

4. Ahmad Z, Idress R, Fatima S, Uddin N, Ahmed A, Minhas K, *et al.* Commonest cancers in Pakistan - Findings and Histopathological Perspective from a Premier Surgical Pathology Center in Pakistan. *Asian Pac J Cancer Prev* 2016;17(3);1061–75.
5. Sarfraz T, Tariq H, Iftikhar N, Raza N, Malik NA, Khan SA, *et al.* Frequency and histological pattern of malignant skin lesions in Pakistani population *Pak Armed Forces Med J* 2019;69(1):83–6.
6. Kim JYS, Kozlow JH, Mittal B, Moyer J, Olencki T, Rodgers P. Guidelines of Care for the Management of Basal Cell Carcinoma. *J Am Acad Dermatol* 2018;78(3);540–59.
7. Dika E, Scarfi F, Ferracin M, Broseghini E, Marcelli E, Bortolani B, *et al.* Basal Cell Carcinoma; A Comprehensive Review. *Int J Mol Sci* 2020;21(15):5572.
8. Quazi S, Aslam N, Saleem H, Rahman J, Khan S. Surgical Margin of Excision in Basal Cell Carcinoma: A Systematic Review of Literature. *Cureus* 2018;12(7):e9211.
9. Davitia M, Lallasb K, Dimitriadisa C, Moutsoudisa A, Eleftheriadisa V, Eftychidoua P, *et al.* Real-Life Data on the Management of Incompletely Excised Basal Cell Carcinoma. *Dermatology* 2023;239(3):429–35.
10. Hunt WTN, Nelson TG. An International Survey Characterizing Mohs Tissue Processing Techniques and Mohs Margin Thresholds: How close is too close? *Clin Exp Dermatol* 2022;47(8):1472–9.
11. Bittner GC, Cerci FB, Kubo EM, Tolkachjov SN. Mohs Micrographic Surgery: A Review of Indications, Technique, Outcomes and Considerations. *An Bras Dermatol* 2021;96(3):263–77.
12. Rehman SH, Majid B, Syed SA, Qureshi MA. "Quantitative Analyses of Skin Cancer Research in Pakistan". *Pak J Med Sci* 2021;37(2):582–7.
13. Kumar S, Mahajan BB, Kaur S, Yadav A, Singh N, Singh A. A study of Basal Cell Carcinoma in South Asians for Risk Factor and Clinicopathological Characterization: A Hospital Based Study. *J Skin Cancer* 2014;2014:173582.
14. Tufail M, Wu C. Cancer statistics in Pakistan from 1994 to 2021; Data from Cancer Registry. *JCO Clin Cancer Inform* 2023;7:e2200142.
15. Cerci FB, Kubo EM, Werner B, Tolkachjov SN. Surgical Margins required for Basal Cell carcinoma treated with Mohs Micrographic Surgery according to Tumour Features. *J Am Acad Dermatol* 2020;83(2):493–9.
16. Tariq S, Saeed A, Ismaeel H, Ullah S, Hamid MA. Rise in the Number of Complex Skin Cancers Necessitates Establishing Mohs Micrographic Surgery Fellowships in Pakistan. *Cureus* 2023;15(8):e43183.
17. van Loo E, Mosterd K, Krekels GA, Roozeboom MH, Ostertag JU, Dirksen CD, *et al.* Surgical excision versus Mohs' Micrographic Surgery for Basal Cell Carcinoma of the Face: A Randomised Clinical Trial with 10 Year Follow-up. *Eur J Cancer* 2014;50(17):3011–20.
18. Tanese K. Diagnosis and Management of Basal Cell Carcinoma. *Curr Treat Options Oncol* 2019;20(2):13.
19. Asif M, Mamoon N, Ali Z, Akhtar F. Epidemiological and Excision Margin Status of Basal Cell Carcinoma - Three Years in Armed Forces Institute of Pathology experience in Pakistan. *Asian Pac J Cancer Prev* 2010;11(5):1421–3.
20. Ullah H, Tahir M, Khan M, Naz S. Frequency of Incomplete Excision of Low Risk Facial Basal Cell Carcinoma with a Safety Margin of Three Millimeter. *Pak J Surg* 2018;34(1):72–7.
21. Ul Kadir SM, Rani Mitra M, Rashid R, Nuruddin M, Hassan Khan MK, Haider G, *et al.* Clinicopathological Analysis and Surgical Outcome of Eyelid Malignancies: A Study of 332 Cases. *J Skin Cancer* 2022;2022:4075668.

22. Bahat AA, Sari M, Listiawan MY, Putra ND, Thendria T, Kurniasari FT, *et al.* The Role of Nicotamide as Chemoprophylaxis in Basal Cell Carcinoma: A Literature Review. *J Pak Assoc Dermatol* 2023;33(4):1669–76.
23. Weshah S, Smadi R, Helalat M. Basal Cell Carcinoma: A Retrospective Analysis of 76 Patients. *Pak J Med Sci* 2007;23(4):556–60.
24. Anandani A, Ganatra MA. Incidence of Basal Cell Carcinoma at Plastic Surgery Department of Tertiary Care Hospital in Karachi. *J Surg Pak* 2011;27(2):117–20.
25. Jaffar N, Kehar SI, Iqbal J, Ghani R, Hasan SM. Morphological Spectrum of Non-Melanoma Skin Cancer Experience at Tertiary Care Hospital in Karachi, Pakistan. *Pak J Med Dent* 2019;8(1):7.
26. Afridi RAK, Ahmed E, Khan SA, Ali A. Demographics Of Basal Cell Carcinoma and its Surgical Management. *J Ayub Med Coll Abbottabad* 2012;24(3-4):141–3.
27. Ito T, Inatomi Y, Nagae K, Nakamura MN, Nakahara T, Furue M, *et al.* Narrow-margin excision is a safe, reliable treatment for well-defined, primary pigmented basal cell carcinoma: an analysis of 288 lesions in Japan. *J Eur Acad Dermatol Venereol* 2015;29(9):1828–31.
28. Otsuka ACVG, Bertolli E, de Macedo MP, Pinto CAL, Duprat Neto JP. Intraoperative Assessment of Surgical Margins Using 'en face' Frozen Sections in the Management of Cutaneous Carcinomas. *An Bras Dermatol* 2022;97(5):583–91.
29. Babar A, Jamal S, Ali SS, Anjum S, Rizvi DA. "Success of Surgical Treatment of Basal Cell Carcinoma; Role of Intraoperative Frozen Section". *Pak Armed Forces Med J* 2018;68(6):1556–60.
30. Schmults CD, Blitzblau R, Aasi SZ, Alam M, Amini A, Bibee K, *et al.* Basal Cell Skin Cancer, Version 2.2024, NCCN Clinical Practice Guidelines in Oncology. *J Natl Compr Canc Netw* 2023;21(11):1181–1203.

Submitted: September 2, 2024

Revised: October 2, 2024

Accepted: November 20, 2024

### Address for Correspondence:

**Prof. Moizza Tahir**, Department of Dermatology, Pak Emirate Military Hospital, Rawalpindi-Pakistan

**Cell:** +92 321 506 3128

**Email:** drmoizzatahir@yahoo.com